

Localized ridge augmentation utilising titanium mesh with CPS morsels and simultaneous implant placement—A case report

Authors: Drs. Lanka Mahesh, Gregori M. Kurtzman, Dildeep Bali, Vishal Gupta & Taran Preet Singh, USA & India

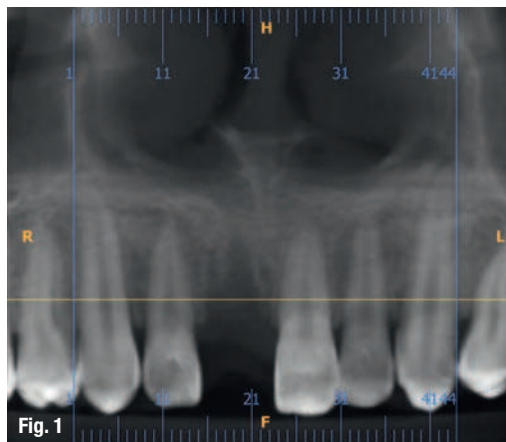


Fig. 1: Loss of maxillary right central incisor.

Implant placement in the atrophic anterior maxilla can often be a difficult task due to deficient bone height, width, and volume. Many procedures have been introduced to aid in the reconstruction of the maxillary alveolar ridge to gain adequate bone to enable implant placement. Surgical modalities for alveolar ridge augmentation, along with guided bone regeneration, has been proven to be successful in re-establishing an appropriate alveolar ridge width. Guided bone regeneration is generally accomplished with the use of particulate bone of various types, and this bone is often protected by membranes. It has been found that the quantity of bone regenerated under the membranes has been demonstrated to be directly related to the amount of the space under the membranes. This space can diminish if the membrane collapses or is compressed, resulting in a less than satisfactory treatment outcome. To avoid the potential problem of membrane collapse, a technique of ridge augmentation is described, which involves the use of a rigid titanium mesh barrier to protect the regenerating tissues and to help protect the underlying bone segments. In this case report, excellent results

were demonstrated for a maxillary anterior defect, augmented using guided bone regeneration with simultaneous placement of an implant to replace the maxillary right central incisor tooth particulate bone graft material protected by titanium mesh. The use of CBCT was essential for the pre-operative diagnostics and useful for demonstrating the volume gain in the post-graft assessment of the site.

Introduction

Resorption of the edentulous or partially edentulous alveolar ridge or bone loss due to periodontitis or trauma frequently compromises dental implant placement in a prosthetically ideal position. These deformities can lead to complications in attempts for the restoration of related areas. Therefore, augmentation of an insufficient bone volume is often indicated prior to, or in conjunction with, implant placement to attain predictable long-term functioning and an aesthetic treatment outcome.¹ In recent years, there has been an increase in the number of studies focusing on the augmentation of these atrophic ridges either before or at the time of implant surgery.²⁻⁶ Predictable bone regeneration of large alveolar defects with complex morphology can pose a significant clinical challenge. Preservation or creation of a soft tissue scaffold needed to create the illusion of a natural tooth, or root eminence for an implant supported restoration is often challenging and difficult to achieve.⁷ A subtle mistake in the positioning of the implant or the mishandling of soft or hard tissue can lead to aesthetic failure and patient dissatisfaction.⁸⁻¹⁰

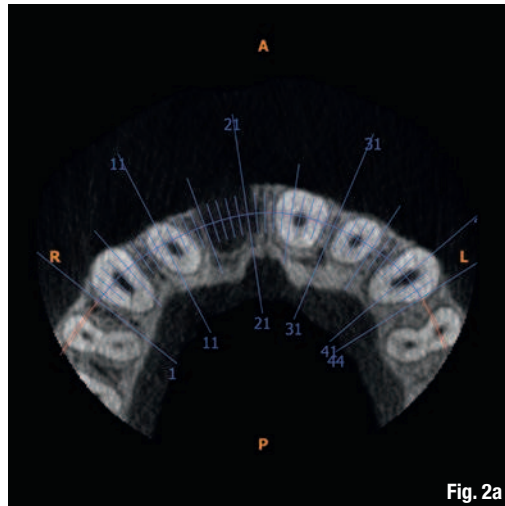
Autogenous bone grafts are considered by many to be the gold standard in bone regeneration procedures.¹¹ However, donor site morbidity, unpredictable resorption, limited quantities available, and the

need to include additional surgical sites are the drawbacks to autografts, which have intensified the search for suitable alternatives. Bone-substitute materials have increased in popularity as adjuncts to or replacements for autografts in bone augmentation procedures to overcome the limitations related to the use of autografts. Bone-substitute materials can be categorised into three groups: (1) allogenic: from another individual within the same species; (2) xenogenic: from another species; or (3) alloplastic: synthetically produced.

The technique of guided bone regeneration (GBR) was evolved to augment atrophic or damaged ridges.¹¹ GBR employs a physical barrier to selectively allow new bone growth into the space created between the barrier and the existing bone.¹² The emergence of synthetic bone substitutes for grafting should enable today's practitioners to perform an almost endless variety of procedures that involve the repair or regeneration of alveolar bone around dental implants or natural teeth. Such materials must satisfy various regulatory requirements and meet clinicians' expectations for safety and effectiveness.¹³ It has been shown that an expanded polytetrafluoroethylene membrane can be used to improve the healing of both pathologic and experimentally created defects; however, this material is not rigid.¹⁴ The rationale of using a titanium mesh is to contain and stabilise the graft with an unyielding material, allowing maximum bone regeneration and minimising overall loss of bone volume. Various forms of titanium mesh have been successfully used to rigidly maintain the alveolar contour with different types of grafts. Graft materials such as alloplastic bone in combination with membranes enhance the treatment success of bone defects.

Case report

A 19-year-old male reported with a missing maxillary right central incisor. The patient gave history of trauma due to accident, which resulted in the loss of the maxillary right central incisor. On clinical examination, deficiency in the anterior residual alveolar ridge with loss of buccal cortical plate was noted. The patient was in good health and was a non-smoker with no medical contraindications for surgery, had excellent oral hygiene and a strong desire to restore the area with a fixed prosthesis. On examination



Figs. 2a–g: CBCT showing the vertical bone loss and deficient labial cortical bone in relation to 11.

there were no clinical signs of periodontitis and dental caries. Radiographically, the clinical findings were verified and revealed vertical and horizontal bone loss that was limited to the maxillary right central incisor (Fig. 2). Using the native software, non-distorted measurements were made on the cross-sectional slices to determine the dimensions of the defect within the residual socket site, and lack of facial cortical-plate as confirmed in the axial view.

Treatment planning

Different treatment options were reviewed with the patient to replace the missing central incisor tooth.

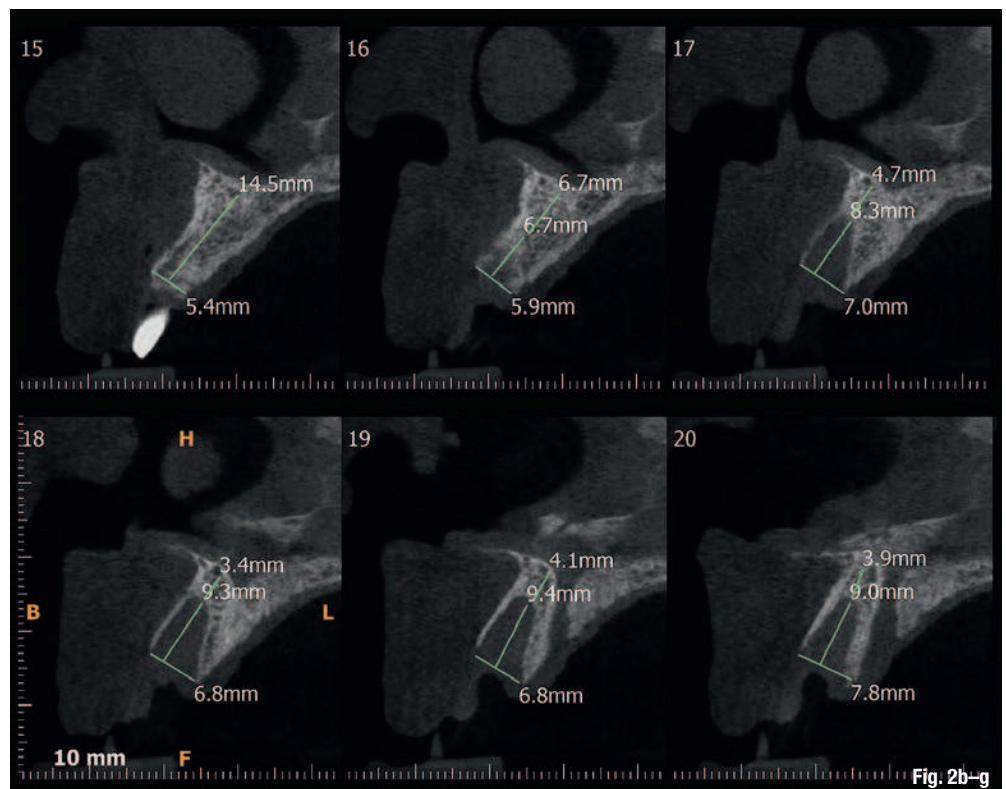


Fig. 2b–g

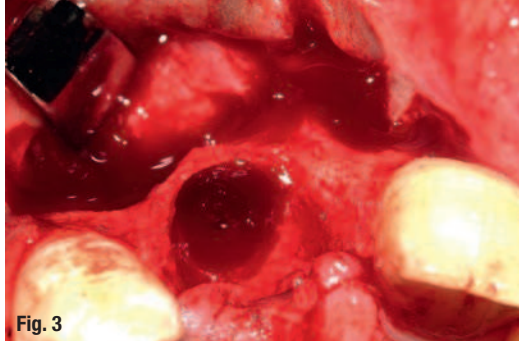


Fig. 3: Bone defect.

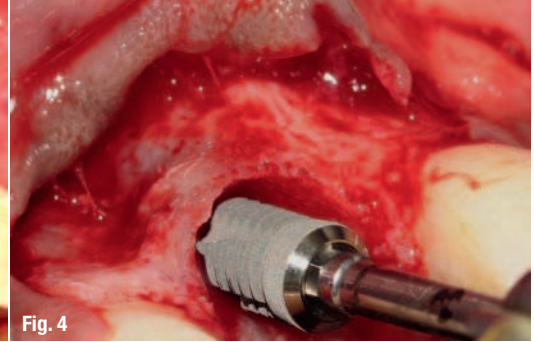


Fig. 4: Surgical placement of implant.

After discussing the pros and cons of each option, it was determined that the most acceptable treatment plan would be an implant-supported restoration. In order to facilitate implant placement, it would also require augmentation of the compromised alveolar ridge using an alloplast bone graft secured with a rigid titanium membrane. The ultimate goal was for a single implant-supported prosthetic replacement.

Treatment procedure

A local anaesthetic agent was administered in the area of the maxillary right upper central incisor. An incision was made on the buccal and palatal aspect of the involved edentulous ridge and a full thickness flap was reflected from the maxillary right lateral to the maxillary left central incisor tooth to reveal the anticipated horizontal and vertical bone defect diagnosed with CBCT imaging (Fig. 3).

Once the soft tissue was removed from the defect area, an osteotomy was prepared under copious irrigation to receive a single implant 3.8 mm in diameter by 11.5 mm in length inserted at 35 Ncm (Kelt Implant) (Fig. 4). Approximately 1 cc of calcium phosphosilicate (CPS) Morsels (NovaBone) (Fig. 5) was mixed with sterile saline and allowed to hydrate before being placed and packed into the defect and positioned to fill all void areas.

A sterile titanium mesh (Fig. 6) was trimmed to size and placed under the facial flap following the GBR protocol to secure the bone graft in its place and was fixated with the cover screw of the implant. Extensive periosteal releasing incisions were made in the facial flap to permit complete tension-free coverage of the membrane. Primary wound closure was obtained by horizontal mattress and interrupted cytoplasm 4/0 sutures (Osteogenics). Post-operative oral hygiene instructions were discussed with the patient.

The patient was seen post-surgically after two weeks for suture removal; no untoward post-operative symptoms were noted. The patient was put on a 2 week, 1 month, 3 month and 6-month recall, ensuring the proper management of implant site. An interim fixed resin-bonded retainer (Maryland Bridge) was utilised during the healing phase. After 5 months, prior to second stage surgery, a post-graft CBCT (Figs. 7a–d) was performed and a horizontal bone gain of 5.3 mm was noted. A comparison of pre- and post-operative CBCT images revealed the extent of bone volume achieved (Figs. 8a & b). The patient was recalled for second stage surgery, where the titanium membrane was removed and the healing collar placed (Figs. 9a & b).

After 3 weeks of additional healing, fixture level impressions were accomplished for the laboratory phase. (Impregum 3M ESPE). The final single tooth

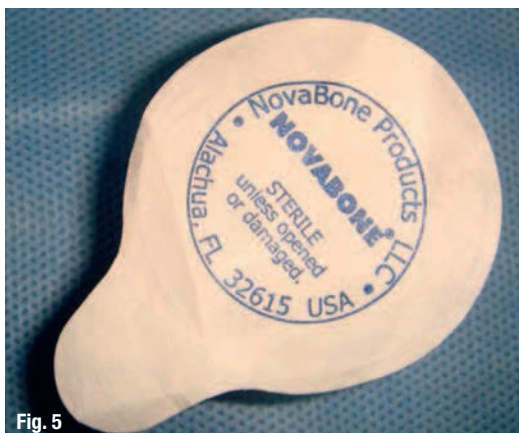

Fig. 5: Novabone CPS.

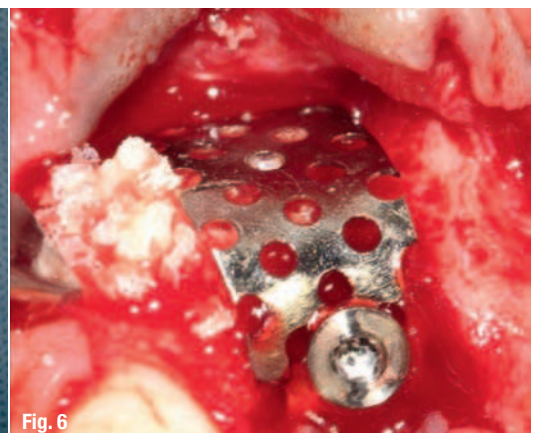


Fig. 6: Placement of bone graft and securing of with titanium mesh.

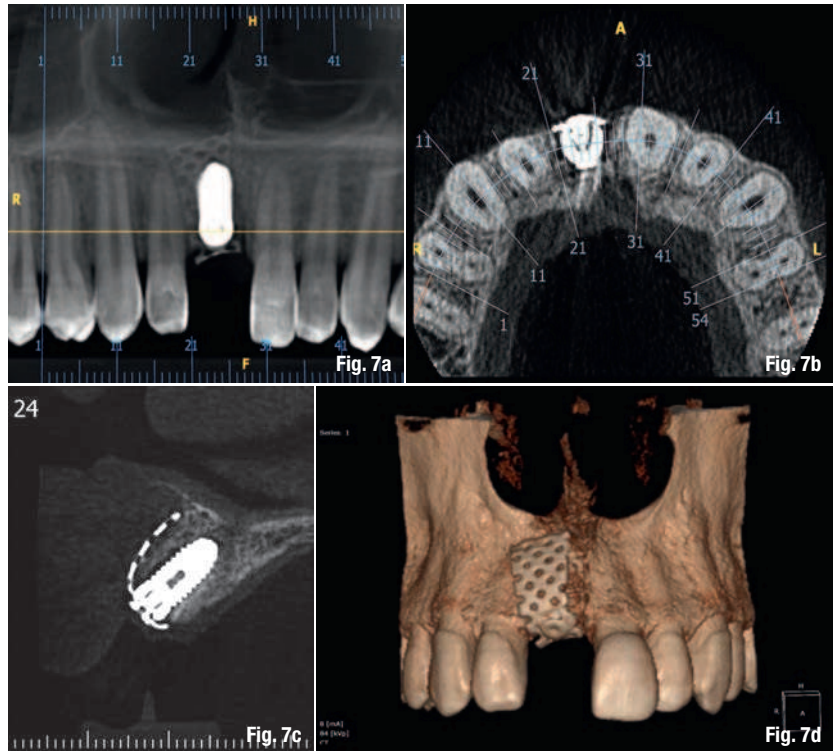
implant-supported prosthesis can be seen in Figs. 10a & b. The post-insertion radiographic image at 14 months revealed excellent bone adaptation surrounding the implant, with sufficient interproximal height of bone (Fig. 11).

Discussion

A differential diagnosis to the cause of the problem associated with the patient's maxillary right central incisor was ambiguous. The patient did present with a history of trauma but the typical findings of wounds, injuries to the oral mucosa, fracture of the tooth, pulp exposure, vitality tests, displacement and mobility¹⁵ were not evident, though the patient did report displacement. Another potential diagnosis could be localised aggressive periodontitis, which exhibits itself typically with small amounts of plaque, mobility and migration of the molars and incisors, an increase in the size of the clinical crown and rapid progression.¹⁶

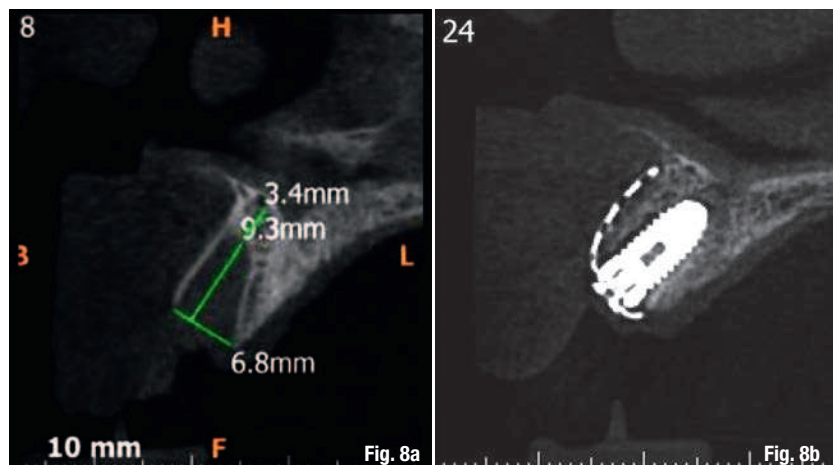
Alternate treatment modalities included a removable partial denture, fixed partial dentures and resin bonded bridges (Maryland bridges). Removable partial dentures, while a viable option, can contribute to the loss of alveolar bone on both abutment and non-abutment teeth.¹⁷ The dissatisfaction rate of removable partial dentures is relatively high.¹⁸ The use of fixed partial dentures would have required the unnecessary destruction of adjacent teeth with pristine tooth structure to prepare anchor abutments. Another option would be a resin-bonded bridge, which would reduce the amount of adjacent tooth destruction but with a high incidence of pontic failure and de-bonding.¹⁹ Using the classification system proposed by Funato et al. 2007, the site in this case was Class IV, which is characterised by vertical and buccal bone loss.²⁰ It was thus necessary to perform bone and tissue augmentation so that optimal gingival profiling and a more aesthetic result could be achieved.

Reconstruction of defects in the anterior part of the maxilla to enable implant placement is a challenging treatment. The alveolar ridge augmentation, along with GBR, has been introduced in recent years to re-establish an appropriate alveolar ridge width. Bone regeneration in membrane-protected defects heal in a sequence of steps that stimulated bone formation after tooth extraction. After blood clot formation, bone regeneration is initiated by the formation of woven bone initially along new blood vasculature at the periphery of the defect. The woven bone is subsequently replaced by lamellar bone, which results in mature bone anatomy. Ultimately, bone remodelling occurs with new, secondary osteons being formed.



Bone graft materials have been used to facilitate bone formation within a given space by occupying that space and allowing the subsequent bone growth. The biologic mechanisms that support the use of bone graft materials are osteoconduction, osteoinduction and osteogenesis. Barrier membranes are biologically inert materials that serve to protect the blood clot and prevent soft tissues cells (epithelium and connective tissue) from migrating into the bone defect, allowing osteogenic cells to be established. Vertical increase of a narrow alveolar crest has been shown to be possible with membranes.^{21, 22} Membranes have been manufactured from biocompatible materials that are both non-resorbable and resorbable. The advantage of a titanium barrier membrane (non-resorbable) is its ability to maintain separation of tissues over an

Figs. 7a–d: Computed tomography scan after 5 months.



Figs. 8a & b: Comparison of pre- and post-operative CBCT.

Figs. 9a & b: Removal of titanium membrane revealing complete bone fill.

Figs. 10a & b: Final implant-supported restoration for the maxillary right central incisor.

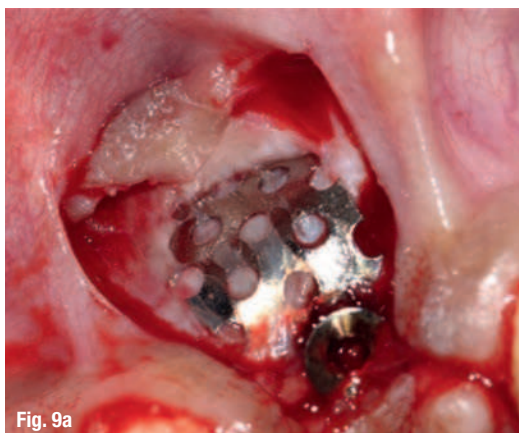


Fig. 9a

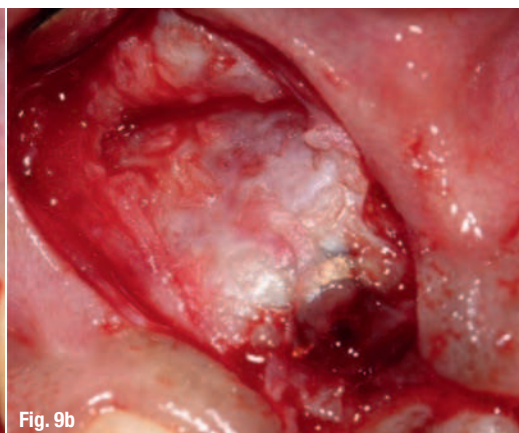

Fig. 9b

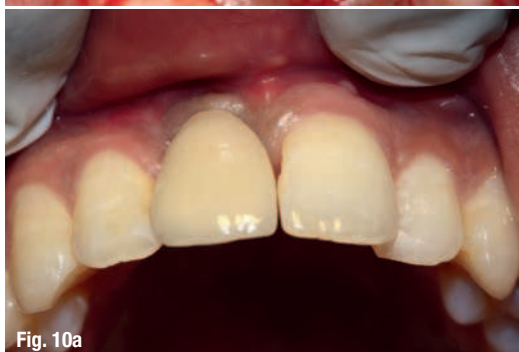

Fig. 10a

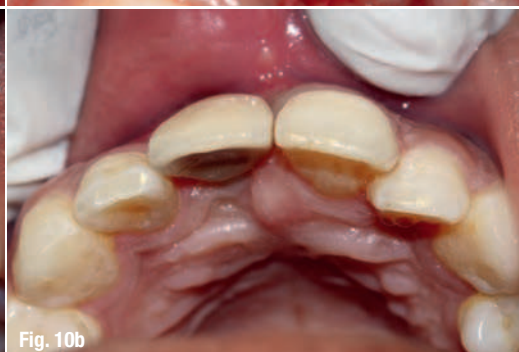

Fig. 10b

extended time. Unless the barrier is exposed, it can remain in place for several months to years but it requires a subsequent surgical procedure to remove them.

Bone augmentation and simultaneous implant surgery procedures allow clinicians to reconstruct alveolar bone deficiencies, preserve alveolar dimensions, and replace missing teeth with dental implants in a prosthetically driven position with natural appearance and function. The 2-year clinical results obtained in this case demonstrate CPS alloplast with GBR along with simultaneous implant placement to be a predictable and successful procedure to augment bone at sites exhibiting insufficient bone volume for implant placement under standard conditions and proved to be a successful strategy for anterior aesthetic rehabilitation.

Fig. 11: Radiograph of implant at 14 months.

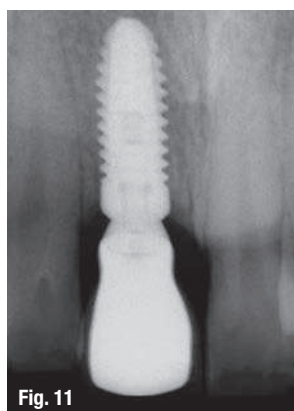


Fig. 11

Conclusion

Placing dental implants in the maxillary anterior region requires precise planning, surgery, and prosthetic treatment. This article illustrated the steps needed to create ideal aesthetics in the maxillary anterior region. Rigorous treatment planning allows the implant surgeon, working with the restorative dentist, to select location, angulation, and spacing of dental implants to achieve ideal aesthetics. Treatment planning also dictates the necessity for hard- and soft-tissue grafting, which is often crucial for an ideal aesthetic result. Further, the

prosthetic restoration of a dental implant must be ideal to achieve the desired aesthetic result. This article has discussed the importance of a comprehensive and interdisciplinary approach to treatment planning, surgery, and restoration of dental implants in the maxillary anterior region of the mouth.

References

1. Buser D, Martin W, Belser UC. Optimizing esthetics for implant restorations in the anterior maxilla: Anatomic and surgical considerations. *Int J Oral Maxillofac Implants* 2004;19 (suppl):43–61.
2. Sigurdsson TJ, Hardwick R, Bogle GC, Wikesjö UM. Periodontal repair in dogs: space provision by reinforced ePTFE membranes enhances bone and cementum regeneration in large supraalveolar defects. *J Periodontol* 1994;65:350–6.
3. Becker W, Becker BE, McGuire MK. Localized ridge augmentation using absorbable pins and e-PTFE barrier membranes: a new surgical technique. Case reports. *Int J Periodontics Restorative Dent* 1994;14:48–61.
4. Shanaman RH. The use of guided tissue regeneration to facilitate ideal prosthetic placement of implants. *Int J Periodontics Restorative Dent* 1992;12:256–65.
5. Buser D, Brägger U, Lang NP, Nyman S. Regeneration and enlargement of jaw bone using guided tissue regeneration. *Clin Oral Implants Res* 1990;1:22–32.
6. Nevins M, Mellonig JT. Enhancement of the damaged edentulous ridge to receive dental implants: a combination of allograft and the GORE-TEX membrane. *Int J Periodontics Restorative Dent* 1992;12:96–111.

7. Magne P, Magne M, Belser U. Natural and restorative oral esthetics. Part I: Rationale and basic strategies for successful esthetic rehabilitations. *J Esthet Dent* 1993;5:161–73.
8. Belser UC, Schmid B, Higginbottom F, Buser D. Outcome analysis of implant restorations located in the anterior maxilla: a review of the recent literature. *Int J Oral Maxillofac Implants* 2004;19 Suppl:30–42.
9. Buser D, Martin W, Belser UC. Optimizing esthetics for implant restorations in the anterior maxilla: anatomic and surgical considerations. *Int J Oral Maxillofac Implants* 2004;19 Suppl: 43–61.
10. Belser U, Buser D, Higginbottom F. Consensus statements and recommended clinical procedures regarding esthetics in implant dentistry. *Int J Oral Maxillofac Implants* 2004;19 Suppl:73–4.
11. Hjørtting-Hansen E. Bone grafting to the jaws with special reference to reconstructive preprosthetic surgery. A historical review [in German]. *Mund Kiefer Gesichtschir* 2002;6:6–14.
12. Mellonig JT, Triplett RG. Guided tissue regeneration and endosseous dental implants. *Int J Periodontics Restorative Dent* 1993;13:108–19.
13. Doblin JM, Salkin LM, Mellado JR, Freedman AL, Stein MD. A histologic evaluation of localized ridge augmentation utilizing DFDBA in combination with e-PTFE membranes and stainless steel bone pins in humans. *Int J Periodontics Restorative Dent* 1996;16:120–9.
14. Lupovici J. Regeneration of the anterior mandible: a clinical case presentation. *J Implant Reconstr Dent* 2009;1:31–4.
15. Andreasen JO. Traumatic injuries of the teeth. chapter 2: examination and diagnosis of dental injuries. Munksgaard. Copenhagen 1972.
16. Carranza FA, Newman MG. Clinical periodontology 8th edition. W. B Saunders Company. Philadelphia 1996.
17. Zlatarić DK, Celebić A, Valentić-Peruzović M. The effect of removable partial dentures on periodontal health of abutment and non-abutment teeth. *J Periodontol*. 2002;73(2):137–44.
18. Frank RP, Milgrom P, Leroux BG, Hawkins NR. Treatment outcomes with Mandibular removable partial dentures: A population based study of patient satisfaction. *J Prosthet Dent*. 1998;80(1): 36–45.
19. Berekally TL, Smales RJ. A retrospective clinical evaluation of resin-bonded bridges inserted at the Adelaide Dental Hospital. *Aust Dent J*. 1993;38(2):85–96.
20. Funato A, Salama MA, Ishikawa T, Garber DA, Salama H. Timing, positioning, and sequential staging in esthetic implant therapy: a four-dimensional perspective. *Int J Periodontics Restorative Dent*. 2007;27(4):313–23.
21. Buser D, Hoffmann B, Bernard JP, Lussi A, Mettler D, Schenk RK. Evaluation of filling materials in membrane-protected bone defects. A comparative histomorphometric study in the mandible of miniature pigs. *Clin Oral Implants Res* 1998;9:137–50.
22. Simion M, Jovanovic SA, Tinti C, Benfenati SP. Long-term evaluation of osseointegrated implants inserted at the time or after vertical ridge augmentation. A retrospective study on 123 implants with 1–5 year follow-up. *Clin Oral Implants Res* 2001;12:35–45.
23. von Arx T, Hardt N, Wallkamm B. The TIME technique: a new method for localized alveolar ridge augmentation prior to placement of dental implants. *Int J Oral Maxillofac Implants* 1996;11:387–94.

about



Dr Lanka Mahesh

is an implantologist practicing in New Delhi, India.

He is a Fellow and Diplomat of the International College of Oral Implantologists (USA) and the Indian Society of Oral Implantologists. He has undergone advanced surgical training in the USA and Spain.

Dr Mahesh has authored 'Practical Guide to Implant Dentistry', published by Quintessence, and has lectured extensively in India and abroad, with numerous publications on implant-related topics.



Dr Gregori Kurtzman

is in private general practice in Silver Spring, Maryland and is a former Assistant Clinical Professor at the University of Maryland, Baltimore School of Dentistry, Department of Endodontics, Prosthetics and Operative Dentistry.

He has lectured both nationally and internationally on the topics of Restorative dentistry, Endodontics and Implant surgery and prosthetics, removable and fixed prosthetics, Periodontics and has over 500 published articles. He is privileged to be on the editorial board of numerous dental publications, a consultant for multiple dental companies, a former Assistant Program Director for a University based implant maxi-course. He has earned Fellowship in the AGD, AAIP, ACD, ICOI, Pierre Fauchard, Academy of Dentistry International, Mastership in the AGD and ICOI and Diplomat status in the ICOI and American Dental Implant Association (ADIA). Dr Kurtzman has been honoured to be included in the 'Top Leaders in Continuing Education' by Dentistry Today annually since 2006. He can be contacted at dr_kurtzman@maryland-implants.com.

Dr Dildeep Bali

Professor of Endodontics
Santosh Dental College
Ghaziabad, India

Dr Vishal Gupta

Private Practice
New Delhi, India

Dr Taran Preet Singh

Private Practice
New Delhi, India